J. Comp. Path. 2015, Vol. ■, 1–10

Available online at www.sciencedirect.com

ScienceDirect

ELSEVIER

www.elsevier.com/locate/jcpa

DISEASE IN WILDLIFE OR EXOTIC SPECIES

Renal Lesions in Cetaceans from Brazil

O. Gonzales-Viera[*,†], V. Ruoppolo[†,‡], J. Marigo[†,§], V. L. Carvalho[‖], K. R. Groch[†], C. P. Bertozzi[§], C. Takakura[¶], G. Namiyama[#], R. E. T. Vanstreels[†] and J. L. Catão-Dias[†]

[*] *Department of Pathology, Microbiology and Immunology, University of California, Davis, CA, USA,* [†] *Laboratório de Patologia Comparada de Animais Selvagens (LAPCOM), Departamento de Patologia, Faculdade de Medicina Veterinária e Zootecnia, Universidade de São Paulo, São Paulo, Brazil,* [‡] *International Fund for Animal Welfare, Yarmouth Port, MA, USA,* [§] *Projeto Biopesca, Praia Grande, São Paulo,* [‖] *Associação de Pesquisa e Preservação de Ecossistemas Aquáticos, Ceará,* [¶] *Laboratório da Disciplina de Patologia de Doenças Transmissíveis, Faculdade de Medicina, Universidade de São Paulo and* [#] *Núcleo de Microscopia Eletrônica, Centro de Procedimentos Interdisciplinares, Instituto Adolfo Lutz, São Paulo, Brazil*

Summary

This study reports the occurrence of renal lesions in cetaceans from the coast of Brazil subjected to necropsy examination between 1996 and 2011. The animals ($n = 192$) were by-caught in fishing nets, were found dead on beaches or died despite attempted rehabilitation. Kidney samples were evaluated grossly and microscopically and, depending on the histopathological findings, immunohistochemical and ultrastructural analyses were conducted. Due to autolysis, a diagnosis was reached in only 128 animals, of which 82 (64.1%) had kidney lesions. Cystic renal disease was the most common lesion observed in 34 cases (26.6%) and these were classified as simple cysts in eight cases (6.3%), polycystic kidney disease in one rough-toothed dolphin (*Steno bredanensis*), secondary glomerulocystic disease in 16 cases (12.5%) and primary glomerulocystic disease in nine cases (7%). Other lesions included membranous glomerulonephritis (28 cases; 21.9%), membranoproliferative glomerulonephritis (20 cases; 15.6%), lymphoplasmacytic interstitial nephritis (21 cases; 16.4%), lipidosis (19 cases; 14.8%), glomerulosclerosis (8 cases; 6.3%) and pyogranulomatous nephritis(five cases; 3.9%); two of the later were associated with the migration of nematode larvae. Additionally, tubular adenoma was identified in a Franciscana (*Pontoporia blainvillei*). The pathological implications of these lesions are discussed according the cause of death, age or sex of the animals. Furthermore, the lesions were compared with those of other marine and terrestrial mammals, including man.

Keywords: cetaceans; cystic renal disease; kidney; pathology

Introduction

Specialized kidneys in cetaceans are an important adaptation to their marine environment (Hedges *et al.*, 1979; Ortiz, 2001). Because of their reniculate morphology and increased medullary thickness, the kidneys play a key role in salt excretion and water conservation (Hedges *et al.*, 1979). In cetaceans and other marine mammals, pathological changes have been described in the lung (Gonzales-Viera *et al.*, 2011; Venn-Watson *et al.*, 2012), liver (Jaber *et al.*, 2004), thyroid gland (Cowan and Tajima, 2006) and pituitary gland (Cowan *et al.*, 2008), but there has been no specific study of renal pathology in these species.

Renal infections are uncommon in cetaceans, and when occur they tend to be related to systemic processes (Sweeney and Ridgway, 1975). *Pasteurella* spp. is a significant bacterial pathogen that can infect the kidneys of cetaceans, causing nephritis as a consequence of acute septicaemia (Dunn *et al.*, 2001).

Correspondence to: O. Gonzales-Viera (e-mail: gonzalesviera@ucdavis.edu).

0021-9975/$ - see front matter
http://dx.doi.org/10.1016/j.jcpa.2015.02.004

Similarly, there are reports of renal mycosis in cetaceans secondary to systemic dissemination of *Candida albicans* (Reidarson *et al.*, 2001), zygomycetes (Robeck and Dalton, 2002) or *Rhizomucor* spp. (Wünschmann et al., 1999). Nematodes such as *Crassicauda* spp. are observed occasionally in kidneys and other tissues, with the tail of adult stages reaching into the calyx to eliminate eggs through the urine (Dailey, 2001). Finally, interstitial nephritis associated with a novel alphaherpesvirus was diagnosed in a Blainvillei's beaked whale (*Mesoplodon densirostris*) (Arbelo *et al.*, 2012) and in a striped dolphin (*Stenella coeruleoalba*) with systemic herpesvirus and morbillivirus co-infection (Soto *et al.*, 2012).

Idiopathic nephritis has been described in a number of cetaceans (Howard, 1983; Di Guardo *et al.*, 1995; Cornaglia *et al.*, 2000); however, this change may have had multiple possible causes that were not clarified (Howard, 1983). Even though cetaceans are known to accumulate a number of chemical carcinogens in their tissues (Martineau *et al.*, 2002), reports of primary renal tumours are less common than those arising in other tissues (Newman and Smith, 2006). Additionally, cystic kidneys of different sizes have been observed in dolphins and other marine mammals and these cysts were considered to be developmental (Howard, 1983).

The aim of the present study was to describe the gross, microscopical, immunohistochemical and ultrastructural features of renal lesions in cetaceans from Brazil.

Materials and Methods

Studied animals were found ashore or incidentally captured along the coast of seven Brazilian States between 1996 and 2011: Rio Grande do Sul, Santa Catarina, Paraná, São Paulo, Rio de Janeiro, Pernambuco and Ceará (Table 1). Necropsy examinations were undertaken by veterinarians or biologists and all tissue samples were deposited in the Marine Mammal Tissue Bank (BTMM) at the Laboratório de Patologia Comparada de Animais Selvagens (LAPCOM), Faculdade de Medicina Veterinária e Zootecnia, Universidade de São Paulo, São Paulo, Brazil. Information about the gender, age and cause of mortality were provided by the staff who performed the examinations. The ages of the animals were estimated based on the total body length or by counting the number of growth layers in the dentine (Kasuya and Brownell, 1979).

Gross and Histological Examination

Gross findings, when present, were recorded on standard forms. Kidney samples were fixed in 10% neutral buffered formalin and processed routinely. Briefly, the tissues were dehydrated through graded alcohols, embedded in paraffin wax, sectioned (3 μm) and stained with haematoxylin and eosin (HE). When appropriate, serial sections were stained by Masson's trichrome, periodic acid–Schiff (PAS), Brown and Bren, Congo red and Ziehl Neelsen stains. The inflammatory, degenerative and cystic findings

Table 1
Information on the cetaceans investigated according their sex, age class and origin

Species	*Number of animals*	*Sex*			*Age class*				*Origin*			
		M	*F*	*NR*	*Adult*	*Juvenile*	*Calf*	*NR*	*By-catch*	*Stranded*	*Rehabilitation*	*NR*
Balaenoptera acutorostrata	2	1	1	–	–	1	–	1	–	1	–	1
Megaptera novaeangliae	2	2	–	–	1	–	1	–	–	2	–	–
Delphinus capensis	2	2	–	–	2	–	–	–	–	1	1	–
Globicephala macrorhynchus	3	3	–	–	–	2	1	–	–	3	–	–
Kogia breviceps	2	1	1	–	2	–	–	–	–	2	–	–
Kogia sima	2	2	–	–	1	–	1	–	–	2	–	–
Lagenodelphis hosei	2	–	2	–	1	1	–	–	–	2	–	–
Mesoplodon europaeus	1	–	1	–	1	–	–	–	–	–	1	–
Peponocephala electra	2	–	2	–	–	2	–	–	–	2	–	–
Physeter macrocephalus	2	–	2	–	–	–	2	–	–	2	–	–
Pontoporia blainvillei	125	71	53	1	36	74	7	8	91	9	22	3
Sotalia guianensis	22	14	8	–	8	5	6	3	6	7	9	–
Stenella clymene	3	1	2	–	3	–	–	–	–	3	–	–
Stenella coeruleoalba	2	–	2	–	2	–	–	–	–	2	–	–
Stenella frontalis	6	4	2	–	4	2	–	–	2	4	–	–
Stenella longirostris	4	3	1	–	1	2	1	–	–	4	–	–
Steno bredanensis	4	3	1	–	1	2	1	–	1	1	1	1
Tursiops truncatus	6	3	2	1	4	1	–	1	1	4	1	–
Total	**192**	**110**	**80**	**2**	**67**	**92**	**20**	**13**	**101**	**51**	**35**	**5**

M, male; F, female; NR, Not recorded.

Please cite this article in press as: Gonzales-Viera O, et al., Renal Lesions in Cetaceans from Brazil, Journal of Comparative Pathology (2015), http://dx.doi.org/10.1016/j.jcpa.2015.02.004

were recorded according to established criteria (Hartman, 1989; Maxie and Newman, 2007; Newman *et al.*, 2012).

Immunohistochemistry

Immunohistochemistry (IHC) was performed to identify special features of the renal lesions. Briefly, selected formalin-fixed tissues were sectioned (3 μm) and antigen retrieval was conducted by incubating sections in citrate buffer (10 mM, pH 9.0) for 5 min in a pressure cooker. Primary antibodies used were mouse monoclonal anti-human pan-cytokeratin (AE1/AE3, M3515, clone AE1/AE3; Dako, Glostrup, Denmark) and anti-human vimentin (M7020, clone Vim 3B4; Dako) diluted 1 in 2,000 and 1 in 3,000, respectively. The EnVision™+ system (Dako) was used as a secondary reagent, and labelling was 'visualized' with 3,3′-diaminobenzidine (Dako). Sections were counterstained with Harris' haematoxylin. Transitional epithelium of the renal pelvis and the fibromuscular band at the corticomedullary junction of reniculi were used as positive internal controls for AE1/AE3 and vimentin, respectively. As negative controls the primary antibodies were replaced by 1% bovine serum albumin.

Ultrastructure

Fragments (1 mm^3) of selected paraffin wax-embedded tissues were used for transmission electron microscopy (TEM). These were reprocessed and fixed in 3% glutaraldehyde, then embedded in Epon Poly/Bed 812-Araldite 502 resin and polymerized at 100°C. Ultrathin sections (70 nm) were contrasted with uranyl acetate and lead citrate and examined using a JEOL® JEM-1011 transmission electron microscope.

Results

Kidney samples from 192 cetaceans (minimum of three reniculi per animal) were collected for microscopical examination during necropsy examination. Eighteen species were included in this study (Table 1), of which Franciscana (*Pontoporia blainvillei*) and Guiana dolphin (*Sotalia guianensis*) were the most common, with 125 and 22 individuals, respectively. In gender evaluation, 110 cetaceans were males, 80 were females and the genders of two animals were not recorded. Of the 192 animals, there were 92 juvenile, 67 adults, 20 calves and 13 with unrecorded ages. A total of 101 were by-caught in fishing nets, 51 were found stranded and 35 died during rehabilitation; in five cases the source was not recorded.

Gross Lesions

The most frequent gross lesions were simple cysts, present in eight cetaceans (seven *P. blainvillei* and one *S. coeruleoalba*). The cysts were distributed randomly only in the cortex of some reniculi, were well demarcated, ranged from 0.2 to 0.7 cm in diameter and were filled by a gelatinous and slightly brown substance (Fig. 1). Additionally, a rough-toothed dolphin (*Steno bredanensis*) had bilateral polycystic disease, in which both kidneys were enlarged (approximately 30 × 15 cm) and had multiple cysts (2–8 cm in diameter) with only a few reniculi retaining normal appearance (Fig. 2).

Histopathology and Immunohistochemistry

Microscopically, 64 samples had varying degrees of autolysis and were unsuitable for diagnosis. Of the remaining 128 samples, 82 (64.1%) had at least one recognizable renal lesion (Table 2) and 46 had no detectable lesions (35.9%).

The main finding was cystic disease in 34 samples (26.6%), which were microscopically classified into four categories. Simple cysts ($n = 8$; 6.3%) were located in the cortex, lined by a simple flat to cuboidal epithelium and were filled with an eosinophilic substance (Fig. 3). IHC showed the cyst lining was positive for AE1/AE3, confirming their tubular epithelial origin. Secondary glomerulocystic disease (SGCD) occurred in 16 cases (12.5%) and was characterized by multiple glomerular cysts with variable quantities of eosinophilic substance in the Bowman's space (Fig. 4). These lesions were considered secondary because of their association with glomerulonephritis and lymphoplasmacytic interstitial nephritis with

Fig. 1. Kidney; *Pontoporia blainvillei*. Transverse section of reniculi with cortical simple cysts (arrows). Bar, 5 mm.

Please cite this article in press as: Gonzales-Viera O, et al., Renal Lesions in Cetaceans from Brazil, Journal of Comparative Pathology (2015), http://dx.doi.org/10.1016/j.jcpa.2015.02.004

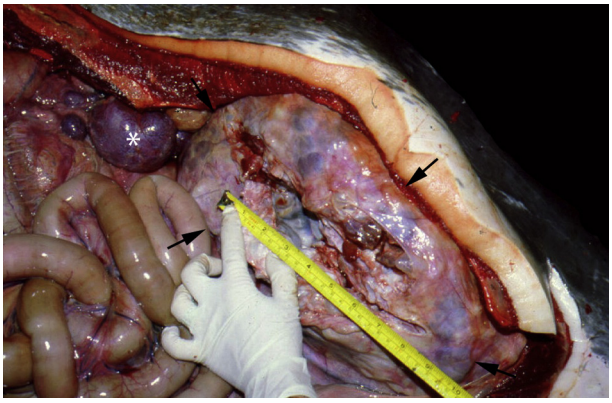

Fig. 2. Kidney; *Steno bredanensis*. Polycystic kidney disease showing kidney enlargement (arrows) with multiple cysts and thickened capsule. Note location of the spleen as an anatomical reference (asterisk). Bar, 2 cm.

varying degrees of interstitial fibrosis. Primary glomerulocystic disease (PGCD) was present in nine cases (7%) with features similar to SGCD; however, it was not associated with intra- or extraglomerular lesions (Fig. 5). Polycystic kidney disease (PKD) was diagnosed in the aforementioned rough-toothed dolphin with bilateral polycystic disease; cysts had varying diameter, glomeruli were absent and a focal area of squamous metaplasia was positive for AE1/AE3 expression (Fig. 6).

Membranous and membranoproliferative glomerulonephritis occurred in 28 (21.9%) and 20 cases (15.6%), respectively. These lesions were characterized by diffuse thickening of the glomerular capillary wall, which was more evident with PAS staining. The difference between these lesions was that membranoproliferative glomerulonephritis had variable proliferation of glomerular cells (Fig. 7). Lymphoplasmacytic interstitial nephritis was observed in 21 cases (16.4%), presenting as an interstitial infiltration of lymphocytes and plasma cells accompanied by variable fibrosis (Fig. 8). Eight cases (6.3%) were diagnosed with varying degrees of glomerulosclerosis, ranging from focal to collapsing (Fig. 9), and in all of these there was interstitial fibrosis and mononuclear cell infiltration. Pyogranulomatous nephritis was observed in five cases (3.9%) and was characterized by necrosis, infiltration of neutrophils, epithelioid and giant cells. In two of these cases nematode larvae were seen within blood vessels (Fig. 10). Tubular adenoma was identified histologically in only one by-caught Franciscana and was composed of tubular proliferation of well-differentiated epithelial cells, which were positive for AE1/AE3 and negative for vimentin (Fig. 11). Additionally, 19 cases (14.8%) had varying degrees of tubular lipidosis.

Ultrastructural Evaluation

Ultrastructural evaluation was performed in three of the best preserved tissues from cases of membranoproliferative glomerulonephritis. Lesions were characterized by thickening of the glomerular capillary basement membrane, moderate intramembranous electron-dense deposits in the Bowman's capsule

Table 2
Renal microscopical diagnoses according to the cetacean species

Species	*MGN*	*MPGN*	*LPIN*	*PGN*	*GS*	*Lipidosis*	*Simple cysts*	*PKD*	*PGCD*	*SGCD*	*Tubular adenoma*
Megaptera novaeangliae	–	1	–	–	–	–	–	–	–	–	–
Delphinus capensis	1	–	–	–	–	–	–	–	2	–	–
Globicephala macrorhynchus	–	–	–	–	–	3	–	–	–	–	–
Kogia sima	–	–	–	–	–	1	–	–	–	–	–
Lagenodelphis hosei	–	1	–	–	–	–	–	–	–	–	–
Mesoplodon europaeus	–	1	–	–	–	–	–	–	1	1	–
Peponocephala electra	1	1	–	–	–	1	–	–	–	–	–
Physeter macrocephalus	–	–	–	–	–	1	–	–	4	–	–
Pontoporia blainvillei	17	7	5	3	3	10	7	–	2	1	1
Sotalia guianensis	2	8	7	2	1	–	–	–	–	11	–
Stenella clymene	3	–	2	–	1	–	–	–	–	–	–
Stenella coeruleoalba	1	–	1	–	1	1	1	–	–	1	–
Stenella frontalis	2	–	2	–	2	–	–	–	–	2	–
Stenella longirostris	–	1	1	–	–	1	–	–	–	–	–
Steno bredanensis	–	–	1	–	–	1	–	1	–	–	–
Tursiops truncatus	1	–	2	–	–	–	–	–	–	–	–
Total	**28**	**20**	**21**	**5**	**8**	**19**	**8**	**1**	**9**	**16**	**1**

MGN, membranous glomerulonephritis; MPGN, membranoproliferative glomerulonephritis; LPIN, lymphoplasmacytic interstitial nephritis; PGN, pyogranulomatous glomerulonephritis; GS, glomerulosclerosis; PKD, polycystic kidney disease; PGCD, primary glomerulocystic disease; SGCD, secondary glomerulocystic disease.

Please cite this article in press as: Gonzales-Viera O, et al., Renal Lesions in Cetaceans from Brazil, Journal of Comparative Pathology (2015), http://dx.doi.org/10.1016/j.jcpa.2015.02.004

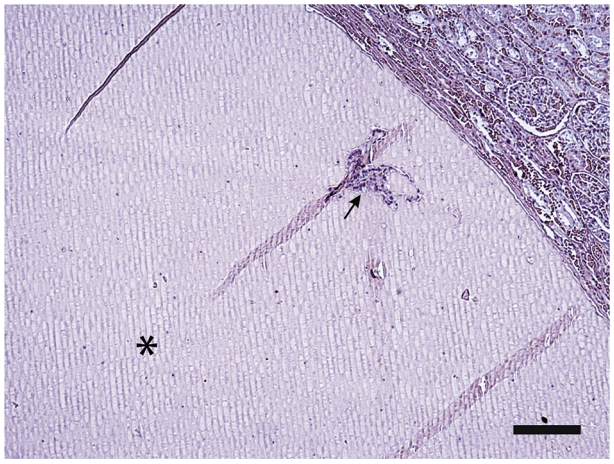

Fig. 3. Kidney; *Pontoporia blainvillei*. Simple cyst filled by an eosinophilic substance (asterisk), with detachment of tubular epithelial cells (arrow) and compression of surrounding parenchyma. HE. Bar, 250 μm.

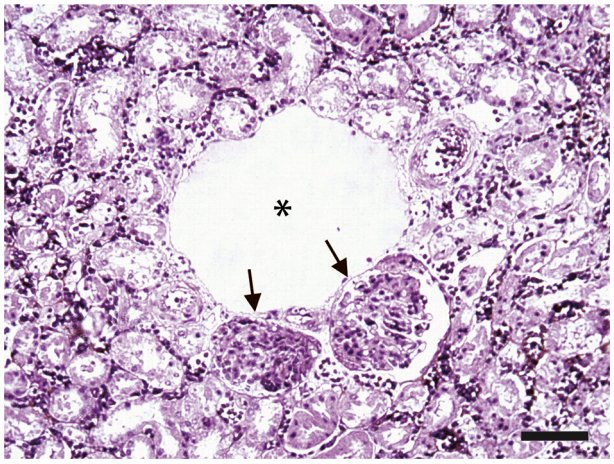

Fig. 5. Kidney; *Pontoporia blainvillei*. Primary glomerulocystic disease, glomerular cyst (asterisk) without glomeruli and intra- or extraglomerular lesion (arrows). HE. Bar, 250 μm.

and glomerular tuft hypercellularity with hypertrophy of endothelial and mesangial cells (Fig. 12). In one case with glomerulosclerosis there was an increase in mesangial matrix and moderate deposits of electron-dense material in the glomerular capillary basement membrane, with the foot processes of the capillary basement membrane fused and marked tortuosity and narrowing of the glomerular capillary lumen. Glomerulosclerotic lesions were accompanied by marked electron-dense deposits in the Bowman's capsule and bundles of electron-dense fibrillar structures with transverse striation consistent with interstitial collagen (Fig. 13).

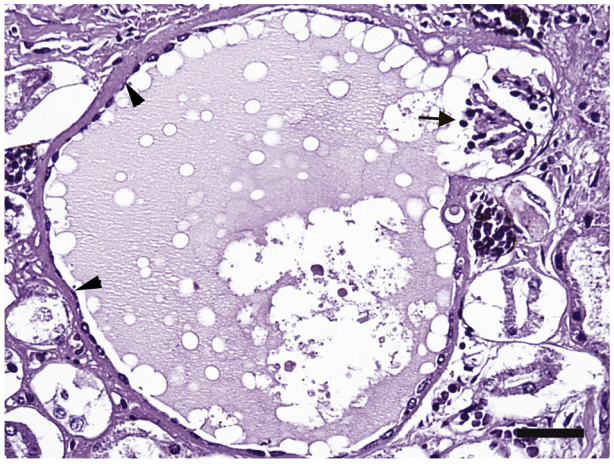

Fig. 4. Kidney; *Pontoporia blainvillei*. Secondary glomerulocystic disease showing dilatation of Bowman's capsule filled by an eosinophilic substance with atrophy of the glomerulus (arrow). There is thickening of the tubular basement membrane and Bowman's capsule (arrowhead). HE. Bar, 100 μm.

Discussion

The most frequent finding in this study was cystic renal disease, which occurred as one of four different types. Simple cysts represent a common incidental finding in man and most domestic and laboratory animals, and generally do not have clinical significance. However, in rare cases they may result in haemorrhage, secondary infection or rupture or may lead to development of carcinomas arising from the wall of the cyst (Hartman, 1989; Maxie and Newman, 2007; Newman *et al*., 2012; Alpers and Fogo, 2013). The simple cysts with tubular origin observed in this study had similar features to those observed in laboratory animals (Jackson *et al*., 2008). In dolphins,

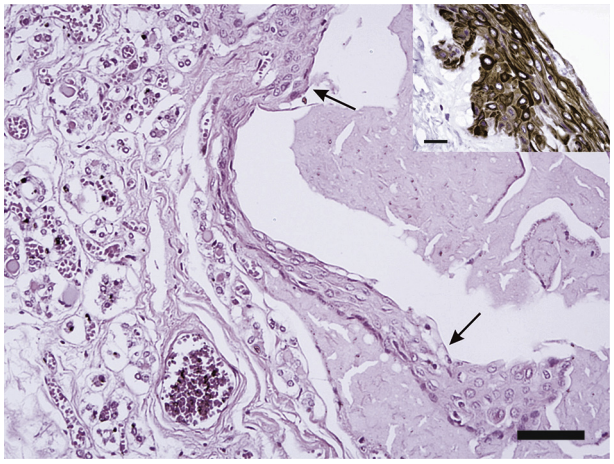

Fig. 6. Kidney; *Steno bredanensis*. Microscopical detail of Fig. 2. There is a large cyst lined by metaplastic squamous epithelium (arrows). HE. Bar, 100 μm. Inset: expression of AE1/AE3 by the squamous cells. IHC. Bar, 25 μm.

Please cite this article in press as: Gonzales-Viera O, et al., Renal Lesions in Cetaceans from Brazil, Journal of Comparative Pathology (2015), http://dx.doi.org/10.1016/j.jcpa.2015.02.004

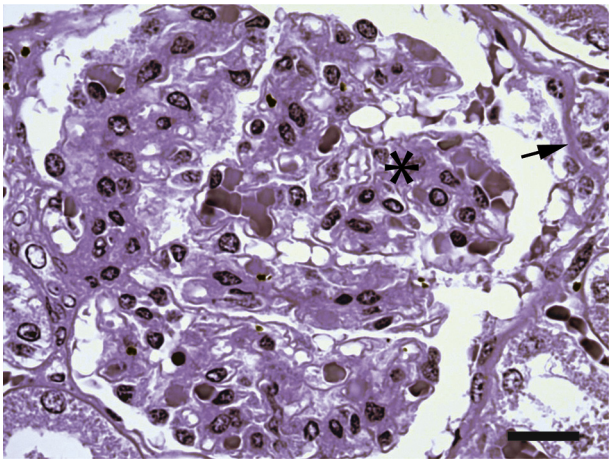

Fig. 7. Kidney; *Sotalia guianensis*. Glomerulus with thickening of the capillary basement membrane and hyperplasia of glomerular cells (asterisk). Note the thickened Bowman's capsule (arrow). HE. Bar, 25 μm.

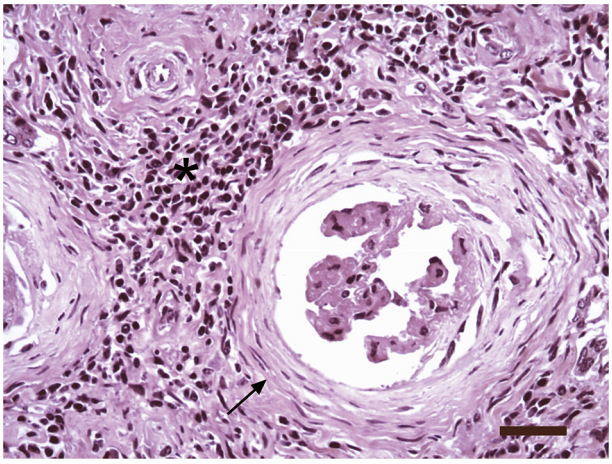

Fig. 9. Kidney; *Stenella coeruleoalba*. Glomerular atrophy with marked Bowman's capsule fibrosis (arrow) and lymphoplasmacytic infiltration with interstitial fibrosis (asterisk), confirmed by Masson's trichrome stain. HE. Bar, 50 μm.

this lesion has been considered a development anomaly as it often occurs in the absence of urinary obstruction (Howard, 1983).

Polycystic kidney disease (PKD) was observed in an adult male rough-toothed dolphin that stranded on the central coast of São Paulo State. In domestic animals, PKD is generally considered a hereditary disease that may occur as either an autosomal dominant condition that affects predominantly adults. PKD in animals is similar to the disease in man, which is associated with defects in the *PKD1* and *PKD2* genes (Hartman, 1989; Alpers and Fogo, 2013), or arises as an autosomal recessive condition that affects mostly calves (Maxie and Newman, 2007; Newman *et al.*, 2012). Because the individual dolphin was an adult and did not have any evidence of urinary obstruction, it is possible that the case was analogous to the autosomal dominant condition described in domestic ungulates (Maxie and Newman, 2007; Newman *et al.*, 2012). However previous toxicological study revealed that this individual dolphin had considerably higher levels of polychlorinated biphenyls PCBs (PCBs; $\sum$26.8 μg/g lipid) and dichlorodiphenyltrichlorothane (DDT) pollutants ($\sum$118 μg/g lipid) than other cetaceans in the same region, and concentration levels similar to those observed in cetaceans from industrialized countries (Yogui *et al.*, 2010). Because PCBs have been found to be associated with the occurrence of PKD in laboratory animals (Maxie and Newman, 2007), another possibility is that this lesion developed due to an unusually high exposure to pollutants by this individual.

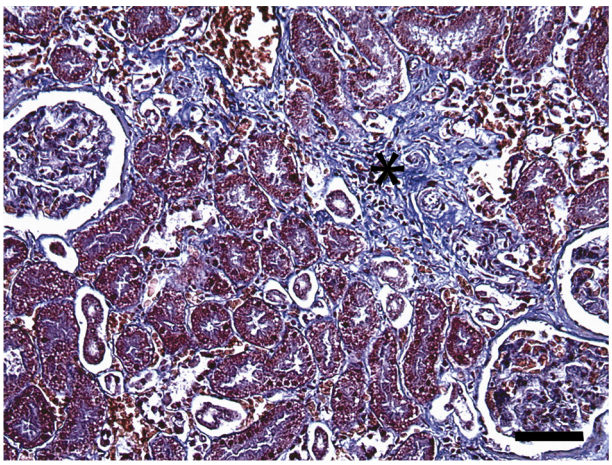

Fig. 8. Kidney; *Stenella coeruleoalba*. Mild interstitial fibrosis (asterisk). Masson's trichrome. Bar, 250 μm.

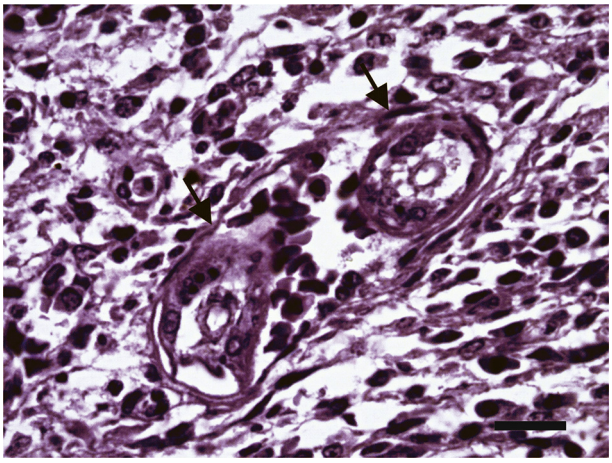

Fig. 10. Kidney; *Sotalia guianensis*. Transverse section of two nematode larvae (arrows) inside a blood vessel. HE. Bar, 25 μm.

Please cite this article in press as: Gonzales-Viera O, et al., Renal Lesions in Cetaceans from Brazil, Journal of Comparative Pathology (2015), http://dx.doi.org/10.1016/j.jcpa.2015.02.004

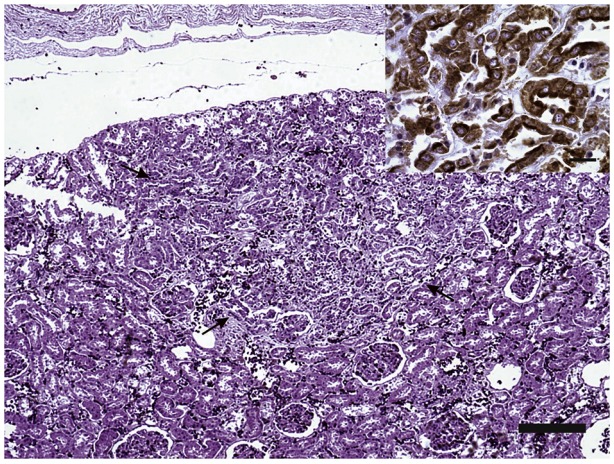

Fig. 11. Kidney; *Pontoporia blainvillei*. Tortuous tubular proliferation (arrows) with mild increase in the amount of parenchyma. HE. Bar, 250 μm. Inset: cytoplasm of tubular epithelial cells expresses AE1/AE3. IHC. Bar, 25 μm.

Fig. 12. Kidney; *Sotalia guianensis*. Moderate electron-dense deposit in the glomerular capillary basement membrane (asterisk), endothelial cell hypertrophy (arrow) and hyperplasia of mesangial cells (arrowhead). TEM. Bar, 2 μm.

The squamous metaplasia observed in this case is also similar to that observed in cases of PKD in domestic ferrets (Jackson *et al*., 2008).

To our knowledge, SGCD and PGCD have not been reported previously in dolphins. In this study, SGCD was considerably less frequent in Franciscana

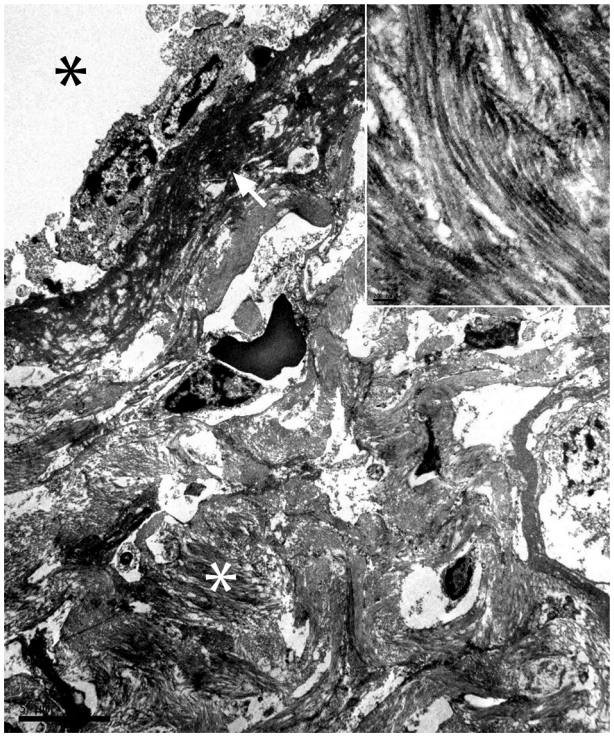

Fig. 13. Kidney; *Stenella coeruleoalba*. Bowman's space (black asterisk) with marked electron-dense deposit in the Bowman's basement membrane (arrow) and interstitial presence of collagen fibres (white asterisk). TEM. Bar, 5 μm. Inset: detail of collagen fibres with transverse striations. TEM. Bar, 200 nm.

than in other cetaceans examined. It must be noted, however, that the Franciscana carcasses in this study were more frequently obtained from incidental bycatch than other cetaceans (91 versus 10). Bycaught cetaceans are more likely to be in better health than those that die during rehabilitation or are found dead on beaches, (Geraci and Lounsbury, 2005), which may indicate that the Franciscanas in this study were less frequently exposed to the predisposing factors of SGCD.

Renal infections are uncommon in cetaceans and, when they occur, tend to be more often associated with infections in other systems (Sweeney and Ridgway, 1975). Membranous and membranoproliferative glomerulonephritis are primary glomerular lesions that are associated with deposition of immune complexes in the glomerular capillary basement membrane, resulting from recurrent antigenaemia from parasitic and microbial infections (Alpers and Fogo, 2013). These lesions often become more prevalent with age and the original cause of the lesion may not always be evident (Maxie and Newman, 2007; Newman *et al*., 2012; Alpers and Fogo, 2013). These lesions are uncommon in cetaceans (Howard, 1983; Gulland *et al*., 2001); however, they have been

reported in other marine mammals such as pinnipeds (Bergman *et al.*, 2001) and polar bears (*Ursus maritimus*) (Sonne *et al.*, 2006, 2007). In polar bears, these lesions are often associated with exposure to organohalogenated compounds and mercury; these pollutants are immunosuppressive and favour recurrent infections after which immune complex deposition occurs (Sonne *et al.*, 2006, 2007). In addition to the deposits on the glomerular basement membrane, cases with a membranoproliferative reaction presented with marked glomerular hypercellularity of mesangial cells. In man and domestic animals, this occurs as a result of immune complex deposition and activation of the complement system, causing the proliferation of glomerular cells and leucocyte infiltration (Newman *et al.*, 2012; Alpers and Fogo, 2013). In cetaceans, membranoproliferative glomerulonephritis has been reported in a beaked whale and may have had the same causes as in terrestrial animals (Howard, 1983).

Interstitial lymphoplasmacytic nephritis has been observed in man and results from both infectious and non-infectious causes (Alpers and Fogo, 2013). In domestic animals, this lesion often has haematogenous origin, being secondary to a systemic or glomerular process (Maxie and Newman, 2007; Newman *et al.*, 2012). In the presents study, virtually all cases of lymphoplasmacytic interstitial nephritis were associated with some level of glomerulonephritis, suggesting a similar pathogenesis.

Five cases were diagnosed with pyogranulomatous nephritis, of which two were associated with nematodes and the remaining three cases did not have any evident causes. In domestic animals, pyogranulomatous nephritis is generally related to a variety of infectious agents (Newman *et al.*, 2012). Although nematodes of the Crassicaudidae family (e.g. *Crassicauda* spp. and *Placentoma* spp.) are known to infect the kidneys of cetaceans (Dailey, 2001), the nematodes observed in this study were smaller than those generally reported for Crassicaudidae, which are usually long and thick (Howard *et al.*, 1983; Dailey, 2001). Additionally, the nematodes found in this study were observed inside blood vessels, similar to those observed in granulomatous lesions associated with larval migration of *Toxocara canis* in dogs and cattle (Maxie and Newman, 2007; Newman *et al.*, 2012).

Glomerulosclerosis is the terminal stage of glomerulonephritis and other chronic renal diseases, with functional failure of the nephron (Newman *et al.*, 2012). It has been reported in a long-finned pilot whale (*Globicephala melas*) and in California sea lions (*Zalophus californianus*) and its pathogenesis in marine mammals is thought to be similar to that of terrestrial mammals (Cowan, 1966; Howard, 1983). In this study, all cases of glomerulosclerosis were accompanied by glomerulonephritis and lymphoplasmacytic interstitial nephritis with variable degrees of fibrosis, suggesting they corresponded to terminal stages of glomerulonephritis caused by immune complex deposition.

The only neoplastic process observed in this study was a tubular adenoma in a by-caught juvenile male Franciscana. This tumour has been reported previously in a by-caught bottlenose dolphin (*Tursiops truncatus*) and, as in this study, it was considered an incidental finding (Migaki *et al.*, 1978). It is believed that this is the first neoplasm reported in Franciscana.

Finally, all cases with renal lipidosis also had hepatic lipidosis (unpublished observations), suggesting that these processes had a common aetiology. In domestic animals and non-human primates, hepatorenal lipidosis is part of a syndrome not yet completely understood (Laber-Laird *et al.*, 1987; Stalker and Hayer, 2007). In cetaceans, this lesion has been associated with a toxic process or nutritional deficiency (Howard, 1983).

In conclusion, this study provides the results of an investigation of renal pathology in cetaceans from the Brazilian coast and may be useful for future comparisons, as kidney pathology is still poorly understood for these species. Furthermore, this work presents conditions not previously reported in dolphins, such as primary and secondary glomerulocystic diseases, and the first report of a tumour in a Franciscana. Overall, our findings corroborate the general interpretation that renal pathological processes in cetaceans are parallel with, and have similar pathogenesis and mechanisms to those in terrestrial mammals.

Acknowledgments

We thank the cetacean associations and rehabilitation centres in Brazil for their contribution of samples for this project. We also thank Conselho Nacional de Pesquisa (CNPq), PEC-PG program for the fellowship provided to OGV and E. Woehler and C. Luján for the English revision. JLCD is the recipient of a scholarship by CNPq. Financial support was provided by FAPESP (99/53956-9) and 00/14669-0. Samples collected by AQUASIS's Projeto Manatí were sponsored by Petrobras Ambiental Program. This study was conducted by OGV as partial fulfillment of the requirements for a Masters degree from the Departamento de Patologia, Faculdade de

Veterinária e Zootecnia, Universidade de São Paulo, São Paulo, Brazil.

Conflict of Interest Statement

The authors declare no conflict of interest.

References

Alpers CE, Fogo AB (2013) Kidney and its collecting system. In: *Robbins Basic Pathology*, 9th Edit., V Kumar, AK Abbas, JC Aster, Eds., Elsevier Saunders, Philadelphia, pp. 517–549.

Arbelo M, Belliére EN, Sierra E, Sacchinni S, Esperón F *et al.* (2012) Herpesvirus infection associated with interstitial nephritis in a beaked whale (*Mesoplodon densirostris*). *BMC Veterinary Research*, **8**, 243.

Bergman A, Bergstrand A, Bignert A (2001) Renal lesions in Baltic grey seals (*Halichoerus grypus*) and ringed seals (*Phoca hispida botnica*). *Ambio*, **30**, 397–409.

Cornaglia E, Rebora L, Gili C, Di Guardo G (2000) Histopathological and immunohistochemical studies on cetaceans found stranded on the coast of Italy between 1990 and 1997. *Journal of Veterinary Medicine Series A*, **47**, 129–142.

Cowan DF (1966) Pathology of pilot whale (*Globicephala melaena*), a comparative study. *Archives of Pathology*, **82**, 78–189.

Cowan DF, Haubold EM, Tajima Y (2008) Histological, immunohistochemical and pathological features of the pituitary gland of odontocete cetaceans from the Western Gulf of Mexico. *Journal of Comparative Pathology*, **139**, 67–80.

Cowan DF, Tajima Y (2006) The thyroid gland in bottlenose dolphins (*Tursiops truncatus*) from the Texas coast of the Gulf of Mexico: normal structures and pathological changes. *Journal of Comparative Pathology*, **135**, 217–225.

Dailey MD (2001) Parasitic diseases. In: *CRC Handbook of Marine Mammal Medicine*, 2nd Edit., LA Dierauf, FMD Gulland, Eds., CRC Press, Boca Raton, pp. 357–379.

Di Guardo G, Agrimi U, Morelli L (1995) Post-mortem investigations on cetaceans found stranded on the coasts of Italy between 1990 and 1993. *Veterinary Record*, **136**, 439–442.

Dunn LJ, Buck JD, Robeck TR (2001) Bacterial diseases of cetaceans and pinnipeds. In: *CRC Handbook of Marine Mammal Medicine*, 2nd Edit., LA Dierauf, FMD Gulland, Eds., CRC Press, Boca Raton, pp. 309–335.

Geraci JR, Lounsbury VJ (2005) Perspectives in strandings and response programs. In: *Marine Mammals Ashore: A Field Guide for Strandings*, 2nd Edit., JR Geraci, VJ Lounsbury, Eds., Texas A&M Sea Grant Publication, Baltimore, pp. 1–309.

Gonzales-Viera O, Chavera A, Yaipén-Llanos C, Perales-Camacho R (2011) Histopathological aspects and etiology of pneumonias in stranded marine mammals from Lima, Peru. *Brazilian Journal of Veterinary Pathology*, **4**, 23–29.

Gulland FMD, Lowenstine LJ, Spraker TR (2001) Noninfectious diseases. In: *CRC Handbook of Marine Mammal Medicine*, 2nd Edit., LA Dierauf, FMD Gulland, Eds., CRC Press, Boca Raton, pp. 521–547.

Hartman DS (1989) An overview of renal cystic disease. In: *Renal Cystic Disease*, DS Hartman, Ed., WB Saunders Company, Toronto, pp. 1–5.

Hedges NA, Gaskin DE, Smith GJD (1979) Renicular morphology and renal vascular system of the harbour porpoise *Phocoena phocoena* (L.). *Canadian Journal of Zoology*, **13**, 868–875.

Howard EB (1983) Miscellaneous diseases. In: *CRC Pathobiology of Marine Mammal Diseases*, EB Howard, Ed., CRC Press, Florida, pp. 164–225.

Howard EB, Britt JO, Matsumoto G (1983) Parasitic diseases. In: *CRC Pathobiology of Marine Mammal Diseases*, EB Howard, Ed., CRC Press, Boca Raton, pp. 120–231.

Jaber JR, Pérez J, Arbelo M, Andrada M, Hidalgo M *et al.* (2004) Hepatic lesions in cetaceans stranded in the Canary Island. *Veterinary Pathology*, **41**, 147–153.

Jackson CN, Rogers AB, Maurer KJ, Lofgren JL, Fox JG *et al.* (2008) Cystic renal disease in the domestic ferret. *Comparative Medicine*, **58**, 161–167.

Kasuya T, Brownell RL Jr. (1979) Age determination, reproduction and growth of the Franciscana dolphin, *Pontoporia blainvillei*. *Scientific Reports of the Whale Research Institute*, **31**, 45–67.

Laber-Laird KE, Jokinen MP, Lehner ND (1987) Fatal fatty liver-kidney syndrome in obese monkeys. *Laboratory Animal Science*, **37**, 205–209.

Martineau D, Lemberger K, Dallaire A, Labelle P, Lipscomb TP *et al.* (2002) Cancer in wildlife a case study: Beluga from the St. Lawrence estuary, Quebec, Canada. *Environmental Health Perspective*, **110**, 285–292.

Maxie MG, Newman SJ (2007) Urinary system. In: *Jubb, Kennedy and Palmer's Pathology of Domestic Animals*, 5th Edit., MG Maxie, Ed., Elsevier, Philadelphia, pp. 425–522.

Migaki G, Woodard JC, Goldston RT (1978) Renal adenoma in an Atlantic bottle-nosed dolphin (*Tursiops truncatus*). *American Journal of Veterinary Research*, **39**, 1920–1921.

Newman SJ, Confer AW, Panciera RJ (2012) The urinary system. In: *Pathologic Basis of Veterinary Diseases*, 5th Edit., JF Zachary, MD McGavin, Eds., Mosby Inc., St Louis, pp. 589–659.

Newman SJ, Smith SA (2006) Marine mammal neoplasia: a review. *Veterinary Pathology*, **43**, 865–880.

Ortiz RM (2001) Osmoregulation in marine mammals. *Journal of Experimental Biology*, **204**, 1831–1844.

Reidarson TH, Mc Bain JF, Dalton LM, Rinaldi MG (2001) Mycotic diseases. In: *CRC Handbook of Marine Mammal Medicine*, 2nd Edit., LA Dierauf, FMD Gulland, Eds., CRC Press, Boca Raton, pp. 337–355.

Robeck TR, Dalton LM (2002) *Saksenaea vasiformis* and *Apophysomyces elegans* zygomycotic infections in bottlenose dolphins (*Tursiops truncatus*), a killer whale (*Orcinus orca*), and pacific white-sided dolphins (*Lagenorhynchus obliquidensis*). *Journal of Zoo and Wildlife Medicine*, **33**, 356–366.

Please cite this article in press as: Gonzales-Viera O, et al., Renal Lesions in Cetaceans from Brazil, Journal of Comparative Pathology (2015), http://dx.doi.org/10.1016/j.jcpa.2015.02.004

Sonne C, Dietz R, Leifsson PS, Asmund G, Born EW *et al.* (2007) Are liver and renal lesions in East Greenland Polar bears (*Ursus maritimus*) associated with high mercury levels? *Environmental Health*, **6**, 1–9.

Sonne C, Dietz R, Leifsson PS, Born EW, Kidkegaard M *et al.* (2006) Are organohalogen contaminants a co factor in the development of renal lesions in East Greenland Polar bears (*Ursus maritimus*)? *Environmental Toxicology and Chemistry*, **25**, 1551–1557.

Soto S, González B, Willoughby K, Maley M, Olvera A *et al.* (2012) Systemic herpesvirus and morbillivirus co-infection in a striped dolphin (*Stenella coeruleoalba*). *Journal of Comparative Pathology*, **146**, 269–273.

Stalker MJ, Hayer M (2007) Liver and biliary system. In: *Jubb, Kennedy and Palmer's Pathology of Domestic Animals*, 5th Edit., MG Maxie, Ed., Elsevier, Philadelphia, pp. 297–388.

Sweeney JC, Ridgway SH (1975) Common diseases of small cetaceans. *Journal of the American Veterinary Medical Association*, **167**, 533–540.

Yogui GT, Santos MCO, Bertozzi CP, Montone RC (2010) Levels of persistent organic pollutants and residual pattern of DDTs in small cetaceans from the coast of São Paulo, Brazil. *Marine Pollution Bulletin*, **60**, 1862–1867.

Venn-Watson S, Daniels R, Smith C (2012) Thirty year retrospective evaluation of pneumonia in a bottlenose dolphin *Tursiops truncatus* population. *Diseases of Aquatic Organisms*, **99**, 237–242.

Wünschmann A, Siebert U, Weiss R (1999) Rhizopusmycosis in a Harbor porpoise from Baltic Sea. *Journal of Wildlife Diseases*, **35**, 569–573.

[*Received, July 7th, 2014*
Accepted, February 19th, 2015]